

• 临床病理讨论 •

Clinicopathological Conference

A 75 year old man with episodic lumbago and fever

(the tenth case)

Case presentation

Institute of Geriatric Cardiology, Chinese PLA General Hospital

The patient, male, 75 year old, was admitted on emergency because of episodic lumbago over 5 months, which got worse accompanied by fever for 5 days on December 3, 2003. The patient had felt paroxysmal lumbago at left side without obvious inducement, accompanied by polyuria, urgency of urination, but without obvious hematuria since June 2003. The body temperature was 40°C. In department of urology of this hospital, the anti-infective agent and symptomatic treatment were given and fine effectiveness was obtained. In the course of treatment, acute ST segment elevation myocardial infarction and multiple organs failure occurred, then he was transferred to the department of cardiology. The patient's condition took a favorable turn and he was discharged after half a month. On November 28, 2003, the patient got fever again without obvious inducement. The body temperature was 39.2°C and the lumbago became worse at the same time. His condition had little improvement after one day, so he came to our hospital. After SARS was ruled out in the fever out-patient clinic, he was admitted on emergency as urinary system infection.

In the past, the patient had diabetes, high blood pressure, coronary heart disease, cerebral hemorrhage, brain atrophy and old cerebral infarction. Cholecystectomy was performed because of biliary calculus 10 years ago. There were no hepatitis and tuberculosis in his past medical history.

Physical examination: T 39.4°C; P 94/min; BR 23/min; BP 136/74 mmHg. He was conscious but apathetic. Breath sound was rough. There was no bubble and wheezing sounds in both lung fields. The heart rate was

94/min, cardiac rhythm was regular, no murmur at any valve auscultation field. There was a 15 cm scar at right upper quadrant of abdomen. Right lower quadrant tenderness was suspected. Rebound tenderness was negative. There was no shifting dullness in abdomen. Spine and limbs were non-deformed. There was no edema at both lower extremities. The myodynamia of left side was grade 4, and that of right side was grade 5. The left upper extremity had in voluntary trembling on lifting. Knee jerk reflex and achilles tendon reflex were decreased. Pathologic reflex was absent. Laboratory examinations: blood routine: WBC $17.6 \times 10^9/L$, neutrophils 0.85; urine routine: erythrocyte 50/ μ L, leucocyte 100/ μ L, protein 25 mg/dl, glucose 1000 mg/dl.

After hospitalization, he was given diabetic diet and treated with antibiotics, controlling blood sugar, reducing the blood pressure, adjusting electrolyte balance and fluid replacement, etc. The patient's condition was improved for a time, but he got fever again on December 20. *Klebsiella pneumoniae* was found in blood culture and he was isolated for treatment. Many kinds of sensitive antibiotics were used, but the fever was not improved at all. During this time, gram-negative bacillus was found many times in blood culture. Through the abdominal CT and lumbar vertebrae X-ray examination, lumbar vertebrae damage and abdominal aortic pseudoaneurysm were found at mid-January 2004 (fig.1, fig.2).

A whole hospital consultation was held and the diagnosis was made as the lumbar vertebrae tuberculosis, paravertebral abscess and abdominal aortic pseudoaneurysm. So antituberculous treatment was initiated. Guided by CT, a liquid opaque area at left upper side of the pseudoaneurysm was punctured and about 5 ml of bloody thick liquid was drawn out. Pathological diagnosis was inflammation; tuberculosis and tumour were

收稿日期:2004-8-20

作者单位:100853 北京市,解放军总医院老年心血管病研究所

作者简介:田进文,男,1970年10月生,山西省大同市人,医学博士,主治医师。Tel:68152402

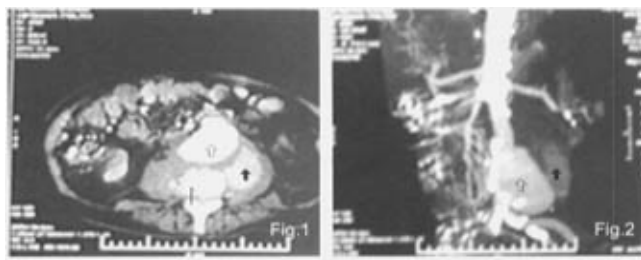


fig. 1 Abdominal CT

↑: Abdominal aortic aneurysm; ↓: Paravertebral abscess; †: Destruction of vertebral body and sequestrum formation

fig. 2 Picture after reconstruction

↑: Abdominal aortic aneurysm; ↓: Paravertebral abscess; .

not found. Anemia occurred in the course of disease, the patient's condition was aggravated gradually. Blood transfusion was given many times and the hemoglobin was maintained at 80 g/L.

The patient stayed in hospital for 132 days altogether. During this period, antituberculous agent, infusion of anti-infective agent, antipyretics, regulating water-electrolyte balance, improving immunity and nutritional support were used, but the condition was aggravated gradually. Two weeks just before dying, the fever became worse obviously, broad-spectrum antibiotic such as Tienam was ineffective. There was large amount

of sputum and moist rales at both bases of the lungs could be heard. Acute left heart failure occurred three times in the last week and all were rescued successfully. At the night of April 12, 2004, Chyne-Stokes respiration occurred and cough reflex decreased. The treatment of suction of sputum and oxygen inhalation was strengthened. At 2:40 of April 13, the patient got respiratory arrest and cardiac arrest suddenly. The rescue course lasted 40 minutes, but all kinds of measures were proved to be ineffective, and the patient was declared to die at 3:20.

Clinical Discussion

Dr. Yin Tong: The main findings of autopsy : There were aortic atherosclerosis and aneurysm in the abdomen. The aneurysm was ruptured and an abscess was formed around it. Hyalinization of arterial wall, thrombosis in lumen of blood vessel and inflammatory necrosis could be found at the rupture site and abscess formed under microscope. There was coronary atherosclerosis, which reached grade III at some sites. Calcification and hyalinization of their wall, as well as hyperplastic fibrous tissue in tunica intima of the vessel could be found under microscope. Small focal fibrosis of left ventricle wall could be found. Some cardiac muscle fibers became necrotic, with neutrophilic infiltration. Pigment deposition could be found on the other cardiac muscle fibers. Both lungs were plump with crepitant feeling, bloody foamy fluid flowed out when they were

pressed after cutting. Congestion and inflammatory cell infiltration of interstitial tissue of the lungs, dilatation of some pulmonary alveoli filled with homogenous pink material could be found under microscope. There was congestion in many organs such as liver, spleen and kidney. Arteriosclerosis occurred in thyroid, spleen and kidneys. Cerebral arteriosclerosis and old cerebral infarction could be found.

Combining the clinical medical history and pathological findings, we think that the cause of the patient's death was that on the basis of atherosclerosis, arterial aneurysm was formed and ruptured, then secondary infection occurred. Based on coronary atherosclerosis and the old myocardial infarction, acute small focal myocardial infarction took place, which caused circulation failure, followed by multiple organ congestion.

At the same time, pulmonary edema occurred and caused body hypoxia, resulting in breathing and circulation function failure and finally death.

Arteriosclerosis could be found in many parts of the body and renal glomerular sclerosis was obvious, which might be related to diabetes or /and high blood pressure. The patient had diabetes and hypertension for many years, arteriosclerosis supported the existence of hypertension and diabetes.

About infection, abscess formation was found beside the abdominal aortic aneurysm close to the vertebral column. It was a non-specific inflammation seen under microscope and had no sign of tuberculosis, so the abscess was a secondary infection caused by rupture of the aneurysm.

Dr. Zhao Shaohong: Two questions about this patient need to be clarified. The first is how the aneurysm is formed, is it a true or false one? The second is what is the etiology of this severe infection. The CT showed that the destruction of lumbar vertebrae was obvious. A possible condition was that the destruction of lumbar vertebrae was a primary lesion, which extended ahead and made abdominal aorta eroded, then the aneurysm was formed. Another condition was that the vertebral body was compressed by aneurysmal dilatation and destroyed. True aneurysm is dilatation of total arterial wall. Its wall has tunica intima, tunica media and tunica adventitia just as normal blood vessel. It is the expansion of cavity only. From the shape of aortic lumen, we can see that the patient's abdominal aorta was not expanded clearly. False aneurysm has two conditions, one is that because of arteriosclerosis, tunica intima and tunica media were damaged, tunica adventitia was expanded by pressure of blood. Another is that the vessel is eroded from outside by external cause, resulting in bleeding which is packed by fibers, so the false aneurysm is formed. The lumen of artery of false aneurysm is not expanded, but damaged at the local site. According to the screenage, the patient's aneurysm was a false one. The origin of it should be infection of lumbar vertebrae. The common cause of lumbar vertebral damage is tuberculosis. The patient was an old man and had diabetes mellitus, so he was apt to suffer from tuberculosis. Lumbar vertebral tuberculosis

caused abscess formation, and the abscess eroded the abdominal aorta, so the false aneurysm was formed. The whole pathophysiological process was caused by abdominal aorta eroded by external infection. From the screenage, we can not define the bacteria causing the infection, but tuberculosis has the highest possibility, although other bacteria can not be ruled out.

Dr. Shen Baoxia: The infection of the patient was a bacterial infection obviously, eumycetes culture was performed many times but nothing was detected. Viral infection is not like this entirely. This condition makes us to think of the tuberculous infection first, but the etiology and pathology did not support the TB. If it was a common bacterial infection, it must not be a single but a mixed infection. The *Staphylococcus epidermidis* which was cultured once may be a contamination. *Klebsiella pneumoniae* which was cultured many times had significance, the abscess might be related to it. However it has not been confirmed whether the *Klebsiella pneumoniae* can damage bone. I agree with Dr. Zhao, the aneurysm is a false one surely.

Dr. Han Li: The autopsy was performed the third day after the patient had died. There might be a flora changing course after death. The *Enterococcus faecalis* and gram-positive bacillus detected in this autopsy are the most common contaminating bacteria. These two bacteria could not explain the whole pathological changes. Although the result of pathological diagnosis did not support the tuberculous infection, it was still a reasonable explanation for the pathophysiological processes. Maybe there was some endogenous standing flora which we did not find had taken a colonization transfer. *Klebsiella* is a kind of aerogen. If it formed such a big abscess, the gas cavity should be showed at screenage, but it was not. Therefore the nature of infection can not be defined certainly.

Dr. Zhao Yusheng: We can judge clearly from our discussion today: The patient's aneurysm was a false aneurysm, and it was formed because of erosion of abdominal aorta damaged by external infection. Because the abscess was in deep part of the body, the infection can not be controlled thoroughly. According to our discussion today, we still can not draw a certain

conclusion about the nature of the infection. The possibility of tuberculous infection which we considered before had no evidence found. *Klebsiella* infection can form abscess, but we could not find direct evidence of it. Moreover there was no any report about destruction of bone matrix by *Klebsiella*. We should find more evidence and will discuss this question further in the future. The

cause of the patient's death is clear and should not have any question since the result of pathophysiological analysis is very correct. We hope every expert to collect the data and reports related to this case, and to study the causes more clearly in the future.

(Translator: TIAN Jinwen, ZHAO Yusheng)

阵发性腰痛、发热 1 例

1 病历摘要

死者,男性,75岁,主因发作性腰痛5月余,加重伴发热5d于2003年12月3日急诊入院。患者于2003年6月无明显诱因出现左侧腰痛,呈阵发性绞痛,伴尿频、尿急,无明显血尿,测体温为40℃。入解放军总医院泌尿科给予抗感染及对症治疗,效果好。但治疗过程中出现急性ST段抬高性心肌梗死及多器官功能不全,转心内科住院半月余,病情好转后出院。2003年11月28日患者再次无明显诱因发热,自测体温为39.2℃,同时感腰痛,在当地医院治疗1d后病情无明显好转,就诊于解放军总医院。经发热门诊排除非典型肺炎后,急诊以泌尿系统感染收入院。

既往患者有糖尿病、高血压、冠心病、脑出血、腔隙性脑梗死、脑萎缩、陈旧性脑梗死病史。10年前因胆结石行胆囊切除术。无肝炎、结核病史。

体格检查:体温37.4℃,心率94次/min,呼吸23次/min,血压136/74 mmHg,神志淡漠,意识清楚;平卧位;双肺呼吸音粗,无干湿啰音,心率94次/min,心律整齐,各瓣膜听诊区未闻及病理性杂音。腹平坦,未见肠型及蠕动波,右下腹压痛可疑,无反跳痛,无明显肌紧张;肝脾肋下未触及,叩诊呈鼓音,右侧肾区叩痛阳性,无移动性浊音,肠鸣音正常。脊柱四肢无畸形,双下肢无浮肿。左侧肌力4级,右侧肌力5级,左上肢抬起时不自主抖动。左侧膝腱反射、跟腱反射减弱。病理反射未引出。辅助检查:血常规:WBC $17.6 \times 10^9/L$,中性0.85;尿常规:红细胞50/ μl ,白细胞100/ μl ,尿蛋白25 mg/dl,糖1000 mg/dl。

住院后给予糖尿病饮食,抗感染、控制血糖、降低血压、补液、调整电解质平衡等治疗,病情一度好

转,体温回落到基本正常。2003年12月20日再次出现发热,血液培养发现有肺炎克雷伯菌,应用多种敏感抗生素治疗,但发热情况未有根本改善,其间还多次培养出革兰阴性杆菌。2004年1月中旬行腹部CT及腰椎X光平片检查,发现腰椎损害及假性腹主动脉瘤,经全院会诊初步确定为腰椎结核,椎旁脓肿伴假性腹主动脉瘤,随即开始抗结核治疗。2004年2月13日在CT引导下对左侧动脉瘤后上方一液性暗区进行了穿刺,抽出血性黏稠液体约5 ml,病理检查结果回报为炎性改变,未发现结核及肿瘤。病程中患者出现贫血,情况逐渐加重,住院期间多次输血,血红蛋白维持在80 g/L左右。

患者共住院132 d,经抗痨、抗感染、退热、调节水电解质平衡、提高患者免疫力及营养支持等多种措施治疗下,病情逐渐发展。临终前两周,发热明显加重,广谱抗生素等治疗无效,痰量较多,双肺底可闻及湿啰音。临终前一周内连续出现3次急性左心衰,均抢救成功。2004年4月12日晚出现陈施呼吸,咳嗽反射减弱,加强了吸痰、吸氧等手段。13日凌晨2:40,突然出现呼吸停止,经过40 min抢救无效,于3:20分死亡。

2 临床病理讨论

尸体解剖主要所见:主动脉粥样硬化,在腹部形成动脉瘤,并出现破裂,局部形成脓肿。镜下见动脉管壁玻璃变性,血管腔内血栓形成,破裂处局部见炎性坏死,脓肿形成。冠状动脉粥样硬化,局部达Ⅲ级,镜下见管壁钙化玻璃变性,血管内膜下纤维组织增生。左心室壁可见小灶状纤维化;局部见心肌纤维坏死,中性白细胞浸润;其余心肌纤维可见色素沉

积。两肺饱满,有捻发音感,切开轻压之有血性泡沫状液体流出。显微镜下见肺间质淤血,炎症细胞浸润,部分肺泡扩张,腔内充满均匀粉染物质。肝、脾、肾等多脏器淤血,脾、肾、甲状腺等多脏器小动脉硬化,脑动脉硬化及陈旧性脑梗死等。

患者全身多处小动脉硬化,肾小球明显硬化,可能与糖尿病或/及高血压有关。解剖时发现在腹主动脉瘤部位近脊柱处有脓肿形成,镜下呈非特异性炎性改变,没有发现结核病的征象。患者的动脉瘤从影像上看是一个假性动脉瘤,其形成的根源应该在腰椎,腰椎受损常见的原因是结核,患者是老年男性,又有糖尿病,因而易患结核,腰椎结核形成脓肿侵蚀了腹主动脉形成了假性动脉瘤。整个病理过程是腹主动脉从外部遭到感染侵蚀引起。从影像上无法确定是何种细菌,结核的可能性最大,但不排除其他细菌。

但病原体和病理学都不支持结核。其他细菌感染可能不是一个单一菌种的情况,而是一个混合感染。多次培养出来肺炎克雷伯菌是有意义的,脓肿的形成很可能与它有关。但它能否对骨质形成破坏尚难肯定。另外,克雷伯菌是产气菌,如果形成这么大的脓肿应该有影像上的气体腔的表现,但没有。因此感染的性质难以确定。

本例患者的死亡原因可能是在动脉粥样硬化的基础上,发生结核或混合细菌感染形成假性动脉瘤;冠状动脉粥样硬化、陈旧性心肌梗死的基础上发生小灶急性心肌梗死,引起循环功能衰竭,继发多脏器淤血。同时出现肺水肿进一步引起机体缺氧,最终导致呼吸循环功能衰竭而死亡。

(参加讨论医师:赵少红,韩黎,沈宝霞,尹彤,赵玉生)

(中国人民解放军总医院老年心血管病研究所

田进文,赵玉生整理)

• 经验交流 •

石家庄市军队离休老年人 20 年因呼吸衰竭死亡分析

高义 王玉敏 王成章 于宝成 潘志刚 齐丽娟 魏士贤

本文总结和分析石家庄市所属部队休干所老年离休干部 20 年间因呼吸衰竭而死亡的病例(55 例)。

1 临床资料

1983 年 1 月至 2002 年 12 月白求恩和平医院收治的因呼吸衰竭死亡病例 55 例,其中男 52 例,女 3 例;年龄 63 ~ 91 岁,平均年龄 77.3 岁。基础疾病:慢性支气管炎伴阻塞性肺气肿 33 例,肺心病 10 例,冠心病 40 例,高血压病 23 例,脑血管病 21 例,糖尿病 9 例,支气管肺癌及纵隔肿瘤 6 例,心力衰竭 5 例,其他疾病 9 例。并发症:上消化道出血 11 例,泌尿系及肠道感染 5 例,多器官功能衰竭 5 例,低钠血症 14 例,低钾血症 8 例,低氯血症 12 例,低蛋白血症 8 例。

血气分析与酸碱失衡:血气分析示 $\text{pH} < 7.3$ 者 16 例, $\text{PaO}_2 < 5.33 \text{ kPa}$ (40 mmHg) 12 例, $\text{PaCO}_2 > 9.33 \text{ kPa}$ (70 mmHg) 10 例。呼吸性酸中毒 16 例,呼吸性酸中毒并代谢性碱中毒 8

例,其他 7 例。

2 讨论

通过对近 20 年老年患者中因呼吸衰竭而死亡的病例统计,主要导致死亡的基础疾病依次为慢性支气管炎阻塞性肺气肿、肺心病、冠心病、高血压、脑血管病等。其死亡诱因亦主要为慢性支气管炎急性发作或肺部感染,其次为支气管肺癌及纵隔肿瘤晚期。本组为高龄患者,多数患有心脑血管病,其动脉硬化、高血压、高血脂、高黏血症等病理过程类同,均可降低心肺及脑的功能,加速呼吸衰竭的过程。由于伴发多种疾病,在呼吸衰竭时更容易出现消化道出血、多器官功能衰竭等各种并发症而导致死亡。在因慢性支气管炎急性发作或肺部感染所诱发呼吸衰竭而死亡的病例中,以 II 型呼吸衰竭为主,呼吸性酸中毒在酸碱失衡类型中所占比例最高,呼吸性酸中毒并代谢性碱中毒占第二位,与文献报道一致,且此类患者并发电解质紊乱的比例较高。在以脑血管病、恶性肿瘤、窒息及其他原因所致呼吸衰竭死亡病例中,以 I 型呼吸衰竭为主,合并酸碱失衡及电解质紊乱者较少。

收稿日期:2004-06-23

作者单位:050082 石家庄市,石家庄白求恩和平医院干部二科

作者简介:高义,女,1958 年 5 月生,河北省石家庄市人,副主任医师。

Tel:0311-7978455